



**PATIENT**

Cordelia Cundesen

**SPECIES**

Canine

**BREED**

Mix

**SEX**

Female Spayed

**AGE**

10.4.07

**WEIGHT**

44.8lbs

**INTERPRETED BY**

Maggie Machen Lamy,  
DVM, DACVIM  
(Cardiology)

**HOSPITAL NAME**

Eastern Animal  
Hospital

**REFERRING VET**

Dr. Michelotti

**INVOICE**

25471

**DATE**

7.21.22

**PRESENTING CLINICAL SIGNS**

History: Presented for annual exam 7/15/22. Grade 3-4/6 left basilar systolic HM noted (historic murmur). Aging changes- lenticular sclerosis, SQ masses.

-Current medications: None listed.

-Sedation used: Butorphanol IV

-Pertinent previous ultrasound results: No previous.

-STAT: Not requested.

-Imaging performed by: Stephanie Pearce RDCS, RVT.

**ELECTROCARDIOGRAPHIC FINDINGS**

A six lead ECG is available at both 25 and 50mm/s; 5mm/mV. The average heart rate is 75bpm (range 60-100bpm). The rhythm is sinus in origin, with a p for every QRS complex and vice versa. The P wave morphology is positive with a normal dimension. Normal PR. The QRS morphology is positive with normal dimension. MEA is normal. No ectopic beats, pauses or dysrhythmias observed.

ECG diagnosis: Normal sinus rhythm with respiratory variation.

**ECHOCARDIOGRAM FINDINGS**

2D, m-mode, color flow and doppler imaging is available. Mild diffuse thickening of mitral valve leaflets with mild prolapse into the left atrial lumen. Mild to moderate eccentric mitral regurgitation with mild left atrial dilation. Normal MR velocity. Normal LV diameter with adequate myocardial function. The tricuspid valve appears normal with trace tricuspid regurgitation. Normal velocity. Normal right atrial and ventricular diameter and morphology indicating no overt evidence of pulmonary arterial hypertension. The pulmonic and aortic valves are normal in morphology and mobility. Normal pulmonic and aortic outflow velocities with laminar flow. No obvious aortic or pulmonic insufficiency. No pericardial or pleural effusion noted. No obvious cardiac masses.

**CARDIAC CHART**

CANINE CARDIAC PARAMETERS	MR VMAX (m/s)	TR VMAX (m/s)	LA/AO (Boon method)	LA/AO (Heart Base; Swe)	FS (%)	EF (%)	EPSS (cm)
NORMAL PARAMETER	4.5-5.5	<2.7	1.3	<1.6	28-40	40-100	<0.6
PATIENT	5.0	2.1	NM	1.3	40	71	NM
CANINE CARDIAC PARAMETERS	HR (BPM)	AV VMAX (m/s)	PV MAX (m/s)	BODY WEIGHT (kg)	LA 2D short axis Base view (cm)	LVIDd Avg; 2D and m-mode short axis (cm)	LVIDs Avg; 2D and m-mode short axis (cm)
NORMAL PARAMETER	50-100	0.7-1.7	0.7-1.6	BELOW	BELOW	BELOW	BELOW
PATIENT	107	1.0	0.5	20.3	2.8	3.7	2.2
*Normal chamber parameters expressed as a mean value (SD)				3	1.27 (5.3)	2.46 (2.46)	1.36 (5.5)
<b>BODY WEIGHT DEPENDENT PARAMETERS</b>				5	1.40 (4.5)	2.74 (5.2)	1.60 (4.7)
<i>*Note: All measurements based upon multi-modal images and methods. An average value is reported.</i>				10	1.50 (3.8)	3.27 (3.5)	2.06 (3.1)
				15	1.83 (2.0)	3.71 (2.4)	2.43 (2.1)
				20	2.02 (1.9)	4.14 (2.2)	2.80 (2.0)
				25	2.18 (2.4)	4.48 (2.9)	3.10 (2.5)
				30	2.33 (3.3)	4.83 (3.9)	3.39 (3.4)
				35	2.48 (4.3)	5.17 (5.0)	3.69 (4.5)
				40	2.62 (5.2)	5.48 (6.1)	3.96 (5.4)
				50	2.88 (7.1)	6.07 (8.3)	4.46 (7.4)

Adapted from June Boon, Veterinary Echocardiography, 1998  
Rishniw M and Hollis NE, J Vet Intern Med 2000; 14:429-435  
Hansson et al, Vet Rad and Ultrasound 2002  
Bonagura et al. Echocardiography: principles of interpretation, Vet Clin North Am 15:1177, 1995

## INTERPRETATION OF THE FINDINGS & FURTHER RECOMMENDATIONS

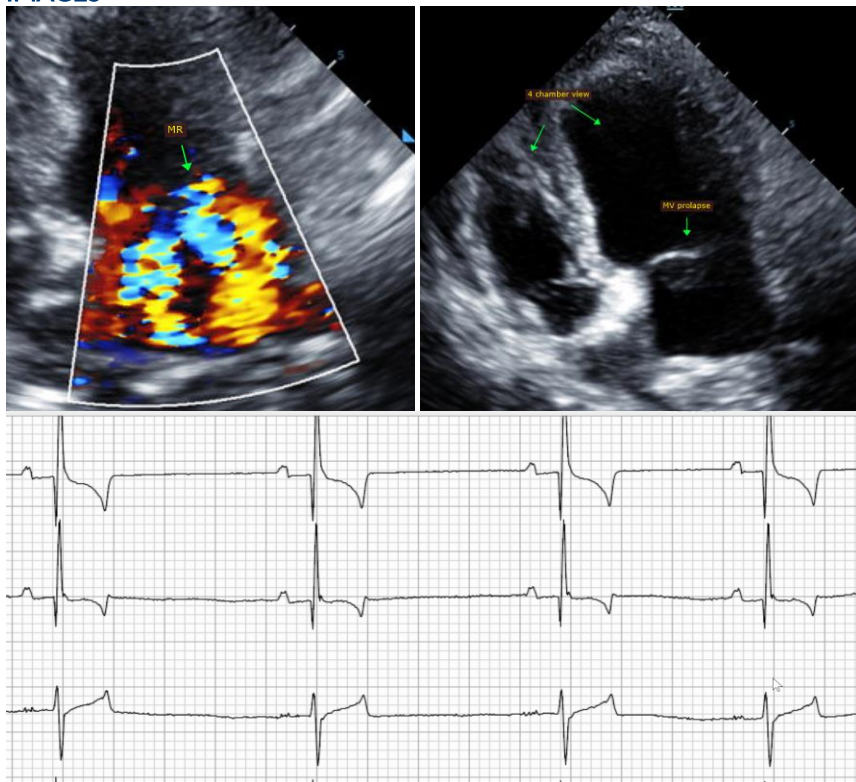
Chronic degenerative valve disease causing mild to moderate mitral and trace tricuspid regurgitation. Lack of significant left atrial enlargement indicates the current risk for complication is low. No concurrent issues such as systolic dysfunction or pulmonary hypertension are noted in this study. The ECG is unremarkable with a respiratory sinus arrhythmia.

In a dog with no significant left atrial enlargement, no cardiac medications are clearly indicated. Assessment of progression in the future will help predict long term prognosis, which is highly variable at this stage (B1). Omega fatty acid supplementation and mild salt restriction may be of some long-term benefit. Monitor for development of a cough, labored breathing, exercise intolerance or collapse episodes.

Anesthetic risk is considered mild if needed. Cardiac protective drug choices (opioid/benzodiazepine premedication, propofol or alfaxalone induction, isoflurane gas) are recommended. Pre-oxygenate for 5-10 minutes prior to induction. Monitor for arrhythmias, hypotension, and hypoxia both intra and post-operatively and intervene as necessary. Mild IV fluid restriction is recommended to avoid fluid overload. Avoid heart rate stimulating drugs such as atropine unless clinically indicated.

Recommend conservative monitoring with a recheck echocardiogram in 6 months, sooner if any development of clinical signs.

## IMAGES



**The information and recommendations provided are based on the images presented by the referring veterinarian. No evaluation can be communicated regarding pathology that was not visible in the image/video clips provided.**

Thank you for this referral. This report was generated using transcription software, and minor dictation errors may be present. If the clinical or image interpretation does not parallel your findings or if I can be of any further assistance, please contact me.

**Maggie Machen Lamy, DVM**  
**Diplomate of the American College of Veterinary Internal Medicine (Cardiology)**  
**info@sonopath.com**